

# Perioperative Point-of-Care Ultrasound

## From Concept to Application

Davinder Ramsingh, M.D., Yuriy S. Bronshteyn, M.D., F.A.S.E., Stephen Haskins, M.D., Joshua Zimmerman M.D., F.A.S.E.

Perhaps the most essential aspect of a physician's role is our diagnostic capabilities. If we cannot accurately diagnose pathology, we cannot effectively treat and may cause patient harm. Point-of-care ultrasound has emerged as a modality to improve bedside assessment. Point-of-care ultrasound refers to the use of ultrasonography at the patient's bedside for diagnostic and therapeutic purposes.<sup>1</sup> The physician acquires and interprets all images in real time and then uses that information to diagnose and direct therapies. While comprehensive imaging can be performed and interpreted at the point-of-care, the term point-of-care ultrasound typically refers to an ultrasound exam that is simple, rapid, and goal-oriented. It is a tool used most often to provide answers to acute "yes or no" clinical questions but can be more sophisticated based on the provider's qualifications. In the acute care setting, this modality has demonstrated utility for nearly every component of bedside assessment, including cardiovascular, pulmonary, airway, and abdominal evaluation.<sup>2-5</sup>

Point-of-care ultrasound has been identified as the most rapidly growing sector in medical ultrasound imaging.<sup>6</sup> Recent advances in this technology include improved image quality as well as a significant reduction in price, with handheld devices costing approximately one twentieth the price of 10 yr ago (from \$40,000+ to \$2,000). These devices are now extremely portable, have intuitive interfaces, and are rapidly integrating methods of automation or semiautomation. Additionally, the integration of artificial intelligence is facilitating pathology identification.<sup>7</sup> With these innovations, the number of specialties utilizing point-of-care ultrasound and the frequency with which point-of-care ultrasound exams are being performed are dramatically increasing.

Thus far, point-of-care ultrasound has gained widespread acceptance in certain acute care specialties, such as emergency medicine and critical care. However, the adoption of many aspects of point-of-care ultrasound has been slower within anesthesiology, even though patients have similar comorbidities and acute care events in the perioperative setting as they do in the emergency and critical care settings.<sup>3</sup> Indeed, events such as pneumothorax, hypovolemia, cardiac

dysfunction, pericardial and pleural effusions, gastric fullness, abdominal bleeding, and pulmonary edema are just a few of the scenarios that are omnipresent. Truly, from a patient care standpoint, why should the skill set for bedside evaluation change simply because the patient entered the perioperative environment? To this point, there has been a significant increase in interest in *perioperative* point-of-care ultrasound.

This clinical focus review seeks to highlight the recent evidence on perioperative point-of-care ultrasound, with a focus on its application for the general anesthesiologist. In addition, we will discuss the topics of training and certification. Finally, we will review the topic of reporting and billing. This article will focus on anesthesiologists in the United States as a review to support the consideration of national society guidelines on the topic.

### Utility of Perioperative Point-of-Care Ultrasound

We summarize the current point-of-care ultrasound topics that have demonstrated utility for the perioperative setting under the following categories: Cardiovascular, Pulmonary and Airway, Abdominal and Pelvic, and Additional Topics. A summary of these topics is highlighted in table 1 and figure 1.

### Cardiovascular Status and Mechanism of Shock

Point-of-care ultrasound has proven to be highly useful for the acute assessment of gross cardiovascular function as well as for the assessment of causes of hemodynamic instability and shock. Point-of-care ultrasound provides several modalities to evaluate both static and dynamic markers of fluid status. For example, ultrasound of the inferior vena cava diameter and left ventricular end-diastolic diameter have shown a strong correlation to central venous pressure and stroke volume, respectively.<sup>8-10</sup> These parameters may be useful for the detection of hypovolemic states. Additionally, the use of Doppler ultrasound to assess the variability of pulsatile flow across cardiac and arterial structures can be used to predict fluid responsiveness.<sup>11,12</sup> This modality provides a dynamic marker that can be used to optimize one's

This article is featured in "This Month in Anesthesiology," page 1A.

Submitted for publication June 24, 2019. Accepted for publication November 27, 2019. Published online first on January 16, 2020. From the Department of Anesthesiology, Loma Linda University Medical Center, Loma Linda, California (D.R.); Duke University Hospital, Durham, North Carolina (Y.S.B.); Department of Anesthesiology, Duke University School of Medicine, Durham, North Carolina (Y.S.B.); Department of Anesthesiology, Critical Care and Pain Management, Hospital for Special Surgery, New York, New York (S.H.); Weill-Cornell Medical College, New York, New York (S.H.); and Department of Anesthesiology, University of Utah Health, Salt Lake City, Utah (J.Z.).

Copyright © 2020, the American Society of Anesthesiologists, Inc. All Rights Reserved. Anesthesiology 2020; 132:908-16. DOI: 10.1097/ALN.0000000000003113

**Table 1.** Perioperative Applications of Perioperative Point-of-Care Ultrasound

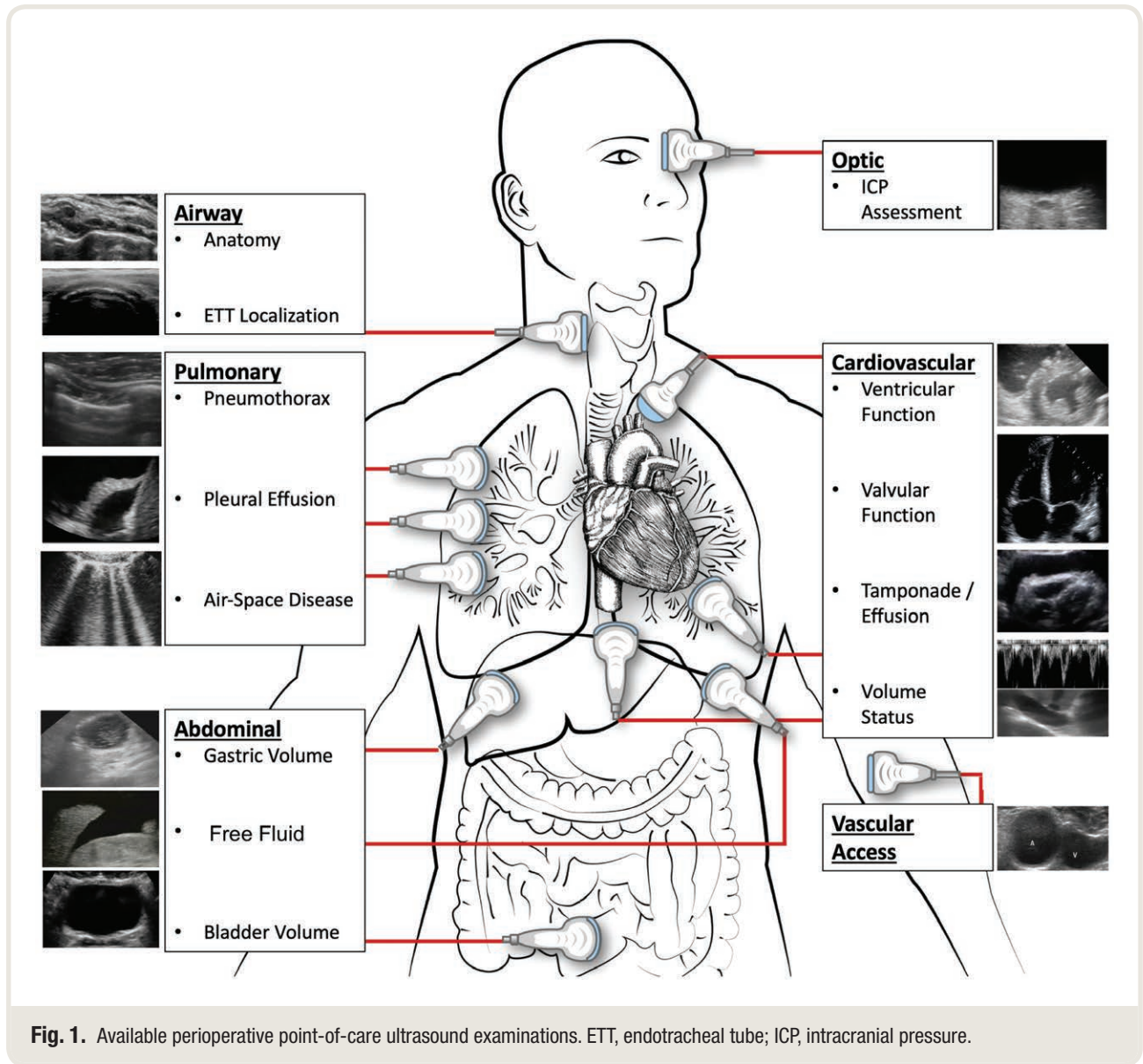
P-POCUS Technique	Preoperative	Intraoperative	Postoperative	Related Evidence-based Protocols
Cardiovascular	<ol style="list-style-type: none"> <li>Pericardial disease</li> <li>Ventricular failure</li> <li>Regional wall motion abnormalities</li> <li>Significant valvular disease</li> <li>Massive pulmonary embolus/deep venous thrombosis</li> </ol>	<ol style="list-style-type: none"> <li>Change in ventricular function</li> <li>New regional wall motion abnormalities</li> <li>Undiagnosed valvular disease</li> <li>New pericardial effusion</li> <li>Evaluation of procedural complications (air, foreign object, etc.)</li> <li>Procedural guidance</li> <li>Assessment during PEA and asystolic arrest</li> </ol>	<ol style="list-style-type: none"> <li>Change in ventricular function</li> <li>New regional wall motion abnormalities</li> <li>New pericardial effusion</li> <li>Pulmonary embolus/deep venous thrombosis</li> <li>Assessment during PEA and asystolic arrest</li> </ol>	BEAT, FATE, FEEL, FoCUS, FORESIGHT, RUSH
Volume status	<ol style="list-style-type: none"> <li>Assess pre-induction volume status</li> <li>Evaluation of central venous pressure</li> </ol>	<ol style="list-style-type: none"> <li>Assess static changes in volume status</li> <li>Detect fluid responsive events</li> </ol>	<ol style="list-style-type: none"> <li>Serial assessment of volume status</li> </ol>	FATE, FORESIGHT, RUSH
Pulmonary and Airway	<p>Assessment for cause(s) of respiratory distress:</p> <ol style="list-style-type: none"> <li>Pneumothorax</li> <li>Pleural effusions</li> <li>Interstitial syndromes</li> <li>Pulmonary edema</li> <li>COPD/Asthma</li> <li>Pneumonia</li> <li>Pulmonary embolism/deep venous thrombosis</li> </ol> <p>Identification/ Management of difficult airway:</p> <ol style="list-style-type: none"> <li>Evaluate markers for difficult airway</li> <li>Visualization of trachea and cricothyroid membrane</li> </ol>	<p>Assessment for procedural complications and worsening of patient pathologies:</p> <ol style="list-style-type: none"> <li>Pneumothorax</li> <li>Diaphragmatic function</li> <li>Hemothorax</li> </ol> <p>Assessment for cause(s) of respiratory distress</p> <ol style="list-style-type: none"> <li>Pneumothorax</li> <li>Pleural effusions</li> <li>Interstitial syndromes</li> <li>Pulmonary edema</li> <li>COPD/Asthma</li> <li>Pneumonia</li> <li>Pulmonary embolus/deep venous thrombosis</li> </ol> <p>Management of airway:</p> <ol style="list-style-type: none"> <li>Endotracheal tube localization (tracheal vs. bronchial)</li> <li>Visualization of trachea and cricothyroid membrane</li> <li>Localization of esophagus</li> </ol>	<p>Assessment for procedural complications and worsening of patient pathologies:</p> <ol style="list-style-type: none"> <li>Pneumothorax</li> <li>Diaphragmatic function</li> <li>Hemothorax</li> </ol> <p>Assessment for cause(s) of respiratory distress</p> <ol style="list-style-type: none"> <li>Pneumothorax</li> <li>Pleural effusions</li> <li>Interstitial syndromes</li> <li>Pulmonary edema</li> <li>COPD/Asthma</li> <li>Pneumonia</li> <li>Pulmonary Embolus/deep venous thrombosis</li> </ol> <p>Management of airway:</p> <ol style="list-style-type: none"> <li>Endotracheal tube localization</li> <li>Visualization of trachea and cricothyroid membrane</li> </ol>	BLUE, FALLS, FATE, FORESIGHT, PLUS, RADIUS, RUSH
Abdominal and Pelvic	<ol style="list-style-type: none"> <li>Assessment of gastric contents/NPO status</li> <li>Trauma assessment for free fluid in the peritoneum</li> <li>Bladder volume assessment</li> </ol>	<ol style="list-style-type: none"> <li>Evaluation of gastric volume collection during surgery</li> <li>Evaluation of abdominal free fluid from surgical complications</li> <li>Bladder volume assessment/urinary catheter assessment</li> </ol>	<ol style="list-style-type: none"> <li>Evaluation of gastric volume collection during surgery</li> <li>Evaluation of abdominal free fluid from surgical complications</li> <li>Bladder volume assessment/ urinary catheter assessment</li> <li>Assessment of abdominal distension and/or ileus</li> </ol>	FAST, FORESIGHT, GUS

BEAT, Bedside Echocardiographic Assessment in Trauma; BLUE, Bedside Lung Ultrasound in Emergency; COPD, chronic obstructive pulmonary disease; FALLS, Fluid Administration Limited by Lung Sonography; FAST, Focused Assessment with Sonography in Trauma; FATE, Focus Assessed Transthoracic Echocardiography; FEEL, Focused Echocardiography in Emergency Life support; FoCUS, Focused Cardiac Ultrasound; FORESIGHT, Focused periOperative Risk Evaluation Sonography Involving Gastroabdominal Hemodynamic and Transthoracic ultrasound; GUS, gastric ultrasound; NPO, *non per os*; PEA, pulseless electrical activity; PLUS, Pulmonary tree and Lung expansion Ultrasound; P-POCUS, perioperative point-of-care ultrasound; RADIUS, Rapid Assessment of Dyspnea with Ultrasound; RUSH, Rapid Ultrasound for Shock and Hypotension.

position on the Frank–Starling curve, similar to techniques such as pulse pressure variation.

Regarding cardiac assessment, point-of-care ultrasound has demonstrated utility for the assessment of pericardial effusions, severe left and right ventricular dysfunction, regional wall motion abnormalities suggestive of coronary artery disease, and gross valvular pathology.<sup>4,13,14</sup> By gaining insight into the presence or absence of these pathologies, one can identify the mechanism of cardiac instability. Indeed, it has been demonstrated that focused

cardiac ultrasound performed by anesthesiologists can accurately detect significant cardiovascular pathology and impact perioperative management.<sup>4,15</sup> Integration of these techniques can be used to determine the mechanism of shock (cardiogenic, obstructive, distributive, and/or hypovolemic) and has also been shown to aid resuscitation for patients in pulseless electrical activity and asystolic arrest.<sup>16</sup> Currently, multiple point-of-care ultrasound-guided cardiovascular protocols have been published,<sup>4,5,17</sup> with the Focus Assessed Transthoracic Echocardiography protocol<sup>18</sup>



**Fig. 1.** Available perioperative point-of-care ultrasound examinations. ETT, endotracheal tube; ICP, intracranial pressure.

being the oldest and most evidence-based for the perioperative setting. Additional protocols have recently been suggested by anesthesiologists, such as a recent step-by-step review on how to perform a bedside focused cardiovascular ultrasound examination.<sup>5</sup> Below are a few bulleted examples in which we have used these protocols to apply cardiac point-of-care ultrasound in the perioperative setting.

- Detection of a pulmonary embolus in a patient hypotensive and hypoxic in recovery after partial hepatectomy
- Identification of severe aortic stenosis in a patient scheduled for urgent hip surgery with the detection of a new murmur
- Detection of enlarging pericardial effusion in a hypotensive patient after a cardiac catheterization procedure
- Detection of reduced systolic function in a parturient patient with worsening shortness of breath

### Pulmonary and Airway

Point-of-care ultrasound has demonstrated a high degree of utility for airway and pulmonary assessment. Perioperative point-of-care ultrasound of the airway has been shown to aid all of the following: identification of difficult airway,<sup>19,20</sup> detection of the appropriate location of the endotracheal tube within the trachea,<sup>21</sup> and assistance with emergent cricothyrotomy procedures.<sup>22,23</sup>

In regard to pulmonary assessments and the evaluation of mechanisms of hypoxia, point-of-care ultrasound has demonstrated superiority to chest x-ray film in diagnosing pneumothorax, pleural effusion, and interstitial alveolar diseases.<sup>24,25</sup> Additionally, pulmonary point-of-care ultrasound is helpful in distinguishing states of pulmonary reactivity (*i.e.*, asthma/chronic obstructive pulmonary disease

exacerbation) from pulmonary parenchymal disease states (*i.e.*, pulmonary edema, atelectasis, pneumonia).<sup>26</sup> Finally, in combination with cardiovascular point-of-care ultrasound, the detection of a pulmonary embolus has also been supported.<sup>26</sup> Each of these components has been integrated into a validated protocol termed the Bedside Lung Ultrasound in Emergency protocol.<sup>26</sup> Other protocols such as the Fluid Administration Limited by Lung Sonography have also proven to be useful for the multifactorial assessment of respiratory failure.<sup>27</sup>

Examples of the application of pulmonary point-of-care ultrasound protocols for the perioperative setting include the following:

- Identification of a large pleural effusion during evaluation for hypoxia in patients undergoing arteriovenous fistula revision
- Detection of pneumothorax intraoperatively in a patient undergoing a laparoscopic Nissen fundoplication with sudden hypotension
- Differentiating obstructive airway disease *versus* congestive heart failure exacerbation in patients with both comorbidities and increasing oxygen requirements

### Abdominal and Pelvic

Commonly used in the emergency room, the Focused Assessment with Sonography for Trauma exam is one of the most highly validated, widely performed point-of-care ultrasound examinations, and is designed to evaluate for free fluid within the pericardium, abdomen, and pelvis.<sup>28</sup> Regarding the perioperative setting, the Focused Assessment with Sonography for Trauma exam has demonstrated utility by identifying the relationship between intraabdominal fluid extravasation after hip arthroscopy and increased pain scores in the postanesthesia care unit.<sup>29</sup> Also integrated into the Focused Assessment with Sonography for Trauma exam is the evaluation of the bladder, which can be helpful in the assessment of decreased urine output. Anecdotally, we have used the Focused Assessment with Sonography for Trauma exam to rapidly diagnose postsurgical abdominal bleeding, which has facilitated the transfer of the patients to the operating room for reexploration.

Additionally, perioperative point-of-care ultrasound can determine the presence of contents (solid or liquid) within the gastric antrum. This technique has been validated as a means to quantify the volume of liquid contents in the stomach.<sup>30</sup> The utility of gastric ultrasound has been demonstrated in a variety of perioperative settings and patient populations, including pregnant, obese, and pediatric patients.<sup>30</sup> Currently, this modality is most often used to help risk-stratify patients and not to alter *non per os* guidelines.

### Additional Applications

As highlighted in this review, point-of-care ultrasound can be used by anesthesiologists to improve their bedside

assessment of common perioperative pathologies. Additional point-of-care ultrasound applications exist that have particular relevance within subspecialties of anesthesiology and for general anesthesiologists in special situations. Examples of these applications include ultrasound for tracheostomy,<sup>4</sup> musculoskeletal/soft tissue ultrasound,<sup>31–33</sup> evaluation of intracranial pressure *via* ocular ultrasound,<sup>4</sup> renal/genitourinary ultrasound,<sup>34</sup> transcranial Doppler ultrasound,<sup>35</sup> and ultrasound for deep venous thrombosis.<sup>36</sup> Additionally, it is essential to recognize that as point-of-care ultrasound becomes more integrated into the perioperative setting, the number of anesthesia-relevant applications will continue to grow. Professional societies involved in the development of training should regularly review additional perioperative point-of-care ultrasound applications.

### Developing Competency

As is often the case with new technologies in medicine, the clinical value of perioperative point-of-care ultrasound has been demonstrated before guidelines and methods of competency training could be established. Anesthesiologists are supported by published guidelines when they perform transesophageal echocardiography and use ultrasound for procedural guidance.<sup>37,38</sup> However, aside from these applications, anesthesiologists' use of point-of-care ultrasound has not previously been backed by professional society guidelines. This lack of guidelines is in contrast to other acute care specialties, which have provided guidance regarding the appropriate scope of practice and have given recommendations for minimum training necessary to achieve competence. This support exists within the American College of Emergency Physicians (Irving, Texas), the Society of Critical Care Medicine (Mount Prospect, Illinois), and the American College of Chest Physicians (Glenview, Illinois).<sup>39,40</sup> However, no such guidance has been available from an anesthesia-specific society. Not surprisingly, the utilization and teaching of diagnostic point-of-care ultrasound among anesthesiologists remains highly variable.<sup>41</sup>

Fortunately, there are supporting initiatives that encourage anesthesiologists to use point-of-care ultrasound. In 1999, the American Medical Association (Chicago, Illinois) passed a resolution<sup>42</sup> that emphasized the following: (1) ultrasound imaging is within the scope of practice of properly trained physicians, and (2) hospitals should grant privileges to perform ultrasound imaging in accordance with specialty-specific guidelines. In 2015, a comprehensive whole-body educational curriculum for anesthesiologists termed the Focused periOperative Risk Evaluation Sonography Involving Gastro-abdominal, Hemodynamic, and Transthoracic ultrasound (FORESIGHT) exam was published as a useful tool for perioperative point-of-care ultrasound education.<sup>4</sup> In 2016, a multispecialty task force reviewed the current applications of perioperative point-of-care ultrasound and its training.<sup>3</sup> This group reported a "call to action" on this topic that emphasized the



following: (1) the importance of our specialty's societies to develop minimum training standards, and (2) the importance of integrating perioperative point-of-care ultrasound training into the anesthesiology residency curriculum.<sup>3</sup>

Additionally, in the past several years, the Accreditation Council for Graduate Medical Education (Chicago, Illinois) and the American Board of Anesthesiology (Raleigh, North Carolina) have identified multiple diagnostic point-of-care ultrasound applications as core competencies for anesthesiologists. The Accreditation Council for Graduate Medical Education recently updated its program requirements for anesthesiology residency programs to state that anesthesiology residents must be trained in the use of surface ultrasound to evaluate "organ function and pathology as related to anesthesia, critical care, and resuscitation." Specific topics listed in the updated program requirements include transthoracic ultrasound for cardiac function/pathology, pulmonary ultrasound, and hemodynamic assessment.<sup>43</sup> Similarly, the American Board of Anesthesiology has recently expanded its board certification content outline to include the following point-of-care ultrasound topics: focused ultrasound of the lungs, inferior vena cava, bladder, and stomach.<sup>44</sup>

### Strategies for Education for the Nontrainee

While the incorporation of perioperative point-of-care ultrasound into an anesthesiology residency is encouraging, there also needs to be an effective strategy for the education of the nontrainee. There are multiple initiatives to further the education of perioperative point-of-care ultrasound through online training and hands-on workshops. The American Society of Anesthesiologists, International Anesthesia Research Society (San Francisco, California), American Society of Regional Anesthesiologists (Pittsburgh, Pennsylvania), Society of Cardiovascular Anesthesiologists (Chicago, Illinois), Society for Pediatric Anesthesia (Richmond, Virginia), and other anesthesia subspecialty societies all host workshops on the topic. Additionally, there are multiple regional and national workshops supported by anesthesiology departments.

Regarding online education, the American Society of Regional Anesthesiologists has integrated a validated online curriculum (<https://usabcd.org/>; accessed January 1, 2020) into its workshops. This curriculum includes the Focus Assessed Transthoracic Echocardiography protocol, which was developed by an anesthesiologist and is one of the most widely referenced point-of-care ultrasound examination protocols. Similarly, the Society of Cardiovascular Anesthesiologists has also previously partnered with an online portal for content training available at <http://www.iteachu.com> (accessed January 1, 2020). Also, in an effort to create free medical education on the topic of perioperative point-of-care ultrasound, the Department of Anesthesiology at Loma Linda University Medical Center (Loma Linda, California) has made the Focused

perioperative Risk Evaluation Sonography Involving Gastroabdominal Hemodynamic and Transthoracic ultrasound curriculum freely available *via* an online platform (<http://www.foresightultrasound.com>; accessed January 1, 2020). Educational tools, including didactic presentations, testing, e-books, podcasts, and virtual reality recordings, are available under an open-source common creative license. A similar process has been developed by the Department of Anesthesiology at the University of Utah (Salt Lake City, Utah; <https://echo.anesthesia.med.utah.edu/tee/focus-content/>; accessed January 1, 2020), with a particular focus on cardiopulmonary pathology.

Other, online resources available for education on perioperative point-of-care ultrasound include those from the Society of Critical Care Medicine (<https://www.sccm.org/Education-Center/Critical-Care-Ultrasound>; accessed January 1, 2020), the American Institute of Ultrasound (Laurel, Maryland; <http://www.aium.org>; accessed January 1, 2020) and Society of Point of Care Ultrasound (San Antonio, Texas; <https://spocus.org>; accessed January 1, 2020). Commercial online products have also recently become available. In addition, there is a newly developed website that provides physician review and database literature on the topic of point-of-care ultrasound, which is free to access at <https://www.ultrasoundgel.org> (accessed January 1, 2020). A full summary of all of the online education resources is beyond the scope of this review; however, an inventory of online educational resources is available at <http://www.sonospot.com> (accessed January 1, 2020).

It is important to realize that, while access to educational content is essential, successful training in perioperative point-of-care ultrasound requires strategies focused on the adult learner along with the performance of clinical examinations.<sup>45</sup> Education that supports self-directed and/or cooperative learning has been demonstrated to be more effective for perioperative point-of-care ultrasound education than traditional pedagogy-based educational strategies.<sup>45</sup> In addition, it is important to recognize the variation in the learning curves between particular point-of-care ultrasound topics as well as among learners with different backgrounds and experiences.<sup>46</sup> Indeed, published guidelines issued by different professional medical societies offer varying recommendations of the minimum training necessary to achieve competence in diagnostic point-of-care ultrasound.<sup>45</sup> This variability further supports the need for anesthesia-specific guidelines for perioperative point-of-care ultrasound competency training.

Currently, routes for obtaining competency are developing both for trainees and practicing anesthesiologists. However, these pathways should be formalized by an anesthesia-specific professional medical society. Fortunately, recent changes have supported this movement. In 2016, the Canadian Anesthesiologists' Society (Toronto, Canada) formed a task force on perioperative point-of-care ultrasound.<sup>47</sup> In the United States, the American Society of

Anesthesiologists has recently supported an *ad hoc* committee to work on this topic as well. Moreover, while society-endorsed pathways for competency training are essential, others have debated the need for the establishment of a certification process as well.<sup>48</sup>

### Reporting and Billing

Reporting and billing for point-of-care ultrasound examinations is a complex subject with many considerations. There are Current Procedural Terminology codes that exist for limited cardiovascular, pulmonary, and abdominal ultrasound examinations, which have recently been summarized by the American College of Emergency Physicians.<sup>49</sup> As defined by the Current Procedural Terminology codes, a complete study is one in which an attempt is made to visualize and diagnostically evaluate all of the major structures within the anatomic description. A limited study would address only a single diagnostic problem or might be a follow-up examination. Regarding point-of-care ultrasound applications, an unmodified ultrasound Current Procedural Terminology code is often used, which describes a combination of professional and technical components as a global service. Integral to this process are three criteria: (1) physician order for point-of-care ultrasound examination, (2) permanent archiving of ultrasound images/clips, and (3) creation of a written report, signed by the interpreting physician, which documents the medical necessity of the examination performed and relevant findings. Development of an archival system that allows for billing, education, and internal quality improvement review is a common barrier.

Application of this process has been most developed by emergency medicine physicians, as expressed through American College of Emergency Physicians.<sup>49</sup> It is important to note, however, that all physicians, regardless of specialty, utilize the same Current Procedural Terminology codes. But without specialty-specific guidelines, anesthesiologists must either (1) surmise proper billing methodology or (2) follow suggestions provided by other professional medical societies that do not use point-of-care ultrasound perioperatively. This lack of guidance propagates the slow adoption of perioperative point-of-care ultrasound as well as supports the practice of performing point-of-care ultrasound examination without documentation (*i.e.*, “phantom-scanning”). During this period of transition, we suggest that anesthesiologists, at minimum, include their perioperative point-of-care ultrasound findings within their physical examination report and archive images. Indeed, as the application of point-of-care ultrasound continues to expand, reevaluation of the appropriateness of current billing strategies will likely be required.

### Limitations of Point-of-Care Ultrasound

Diagnostic point-of-care ultrasound, like any other clinical tool, is capable of benefiting as well as causing harm to patients. The known risks of diagnostic point-of-care

ultrasound are, in general, similar to the risks of a physical exam performed with a stethoscope: (1) the risk of transmitting harmful pathogens between patients, and (2) the risk of misinterpretation of data derived from the exam. Indeed, low sensitivity of pathology detection between point-of-care ultrasound exams performed by novice users to complete ultrasound exams has been reported.<sup>50</sup> Also, similar to the stethoscope, patient characteristics such as obesity<sup>27</sup> may impact the ability to perform a point-of-care ultrasound exam. Thus, it is crucial that clinician-sonographers recognize their limits and understand when a poor image should be disregarded, when pathology is ambiguous, and when consultation with more experienced colleagues or specialists is required.<sup>5</sup> Additionally, ultrasound energy increases the temperature of nearby tissue. Because of this potential for thermal injury, anesthesiologists performing point-of-care ultrasound should aim to keep ultrasound exposure as low as reasonably achievable for all organs, especially the eye and fetal tissues.<sup>51</sup> Also, it is important to highlight that the majority of evidence for the utility of perioperative point-of-care ultrasound is limited to nonrandomized single-center studies. Indeed, we are not aware of any large multicenter randomized control studies evaluating the utility of perioperative point-of-care ultrasound. Finally, in the discussion of the benefit-to-risk ratio of perioperative point-of-care ultrasound, it is important to recall that ultrasound for vascular access, peripheral nerve blocks, and intraoperative transesophageal echocardiography was controversial when first introduced, but has now become common practice within the anesthesiology specialty.

### Conclusions

While there is still much to be developed, the concept of perioperative point-of-care ultrasound has shown dramatic growth in recent years. Further innovation and integration of this tool have tremendous potential for impacting perioperative care by providing real-time explanations for many acute care events. The onus is on our specialty and our colleagues to develop structured guidelines, support educational pathways for the trainee and postgraduate learner, and evaluate credentialing processes to incorporate perioperative point-of-care ultrasound into everyday practice.

### Research Support

Support was provided solely from institutional and/or departmental sources.

### Competing Interests

Dr. Ramsingh is a consultant for Edwards Lifesciences (Irvine, California), General Electric (Boston, Massachusetts), and Fujifilm Sonosite (Bothell, Washington), and had research funded by Edwards Lifesciences, General Electric,

Merck Pharmaceuticals (Kenilworth, New Jersey), Pacira Pharmaceuticals (Parsippany, New Jersey), and the Masimo Corporation (Irvine, California). The other authors declare no competing interests.

### Correspondence

Address correspondence to Dr. Ramsingh: Department of Anesthesiology and Perioperative Care, Loma Linda University Medical Center, Loma Linda, California 92354. dramsingh@llu.edu. Information on purchasing reprints may be found at [www.anesthesiology.org](http://www.anesthesiology.org) or on the masthead page at the beginning of this issue. ANESTHESIOLOGY's articles are made freely accessible to all readers, for personal use only, 6 months from the cover date of the issue.

### References

- Moore CL, Copel JA: Point-of-care ultrasonography. *N Engl J Med* 2011; 364:749–57
- Haskins SC, Boublik J, Wu CL: Point-of-Care ultrasound for the regional anesthesiologist and pain specialist: A series introduction. *Reg Anesth Pain Med* 2017; 42:281–2
- Mahmood F, Matyal R, Skubas N, Montealegre-Gallegos M, Swaminathan M, Denault A, Sniecinski R, Mitchell JD, Taylor M, Haskins S, Shahul S, Oren-Grinberg A, Wouters P, Shook D, Reeves ST: Perioperative ultrasound training in anesthesiology: A call to action. *Anesth Analg* 2016; 122:1794–804
- Ramsingh D, Rinehart J, Kain Z, Strom S, Canales C, Alexander B, Capatina A, Ma M, Le KV, Cannesson M: Impact assessment of perioperative point-of-care ultrasound training on anesthesiology residents. *ANESTHESIOLOGY* 2015; 123:670–82
- Zimmerman JM, Coker BJ: The Nuts and Bolts of Performing Focused Cardiovascular Ultrasound (FoCUS). *Anesth Analg* 2017; 124:753–60
- P & S Market Research: Point-of-Care Ultrasound (PoCUS) Device Market to Grow at 6.9% CAGR till 2025: P&S Market Research Available at: <https://www.globenewswire.com/news-release/2017/07/21/1055557/0/en/Point-of-Care-Ultrasound-PoCUS-Device-Market-to-Grow-at-6-9-CAGR-till-2025-P-S-Market-Research.html>. Accessed February 4, 2019.
- Shokoohi H, LeSaux MA, Roohani YH, Liteplo A, Huang C, Blaiwas M: Enhanced point-of-care ultrasound applications by integrating automated feature-learning systems using deep learning. *J Ultrasound Med* 2019; 38:1887–97
- Cannesson M, Sliker J, Desebbe O, Farhat F, Bastien O, Lehot JJ: Prediction of fluid responsiveness using respiratory variations in left ventricular stroke area by transoesophageal echocardiographic automated border detection in mechanically ventilated patients. *Crit Care* 2006; 10:R171
- Scheuren K, Wentz MN, Hainer C, Scheffler M, Lichtenstern C, Martin E, Schmidt J, Bopp C, Weigand MA: Left ventricular end-diastolic area is a measure of cardiac preload in patients with early septic shock. *Eur J Anaesthesiol* 2009; 26:759–65
- Subramaniam B, Talmor D: Echocardiography for management of hypotension in the intensive care unit. *Crit Care Med* 2007; 35(suppl 8):S401–7
- Broch O, Renner J, Gruenewald M, Meybohm P, Hocker J, Schottler J, Steinfath M, Bein B: Variation of left ventricular outflow tract velocity and global end-diastolic volume index reliably predict fluid responsiveness in cardiac surgery patients. *J Crit Care* 2012; 27: 325 e7–13
- Charron C, Caille V, Jardin F, Vieillard-Baron A: Echocardiographic measurement of fluid responsiveness. *Curr Opin Crit Care* 2006; 12:249–54
- Coker BJ, Zimmerman JM: Why anesthesiologists must incorporate focused cardiac ultrasound into daily practice. *Anesth Analg* 2017; 124:761–5
- Fagley RE, Haney MF, Beraud AS, Comfere T, Kohl BA, Merkel MJ, Pustavoitau A, von Homeyer P, Wagner CE, Wall MH; Society of Critical Care Anesthesiologists: Critical care basic ultrasound learning goals for American anesthesiology critical care trainees: Recommendations from an expert group. *Anesth Analg* 2015; 120:1041–53
- Cowie B: Three years' experience of focused cardiovascular ultrasound in the peri-operative period. *Anaesthesia* 2011; 66:268–73
- Breitkreutz R, Price S, Steiger HV, Seeger FH, Ilper H, Ackermann H, Rudolph M, Uddin S, Weigand MA, Müller E, Walcher F; Emergency Ultrasound Working Group of the Johann Wolfgang Goethe-University Hospital, Frankfurt am Main: Focused echocardiographic evaluation in life support and peri-resuscitation of emergency patients: A prospective trial. *Resuscitation* 2010; 81:1527–33
- Haskins SC, Tanaka CY, Boublik J, Wu CL, Sloth E: Focused cardiac ultrasound for the regional anesthesiologist and pain specialist. *Reg Anesth Pain Med* 2017; 42:632–44
- Holm JH, Frederiksen CA, Juhl-Olsen P, Sloth E: Perioperative use of focus assessed transthoracic echocardiography (FATE). *Anesth Analg* 2012; 115:1029–32
- Reddy PB, Punetha P, Chalam KS: Ultrasonography – A viable tool for airway assessment. *Indian J Anaesth* 2016; 60:807–13
- Fulkerson JS, Moore HM, Anderson TS, Lowe RF Jr: Ultrasonography in the preoperative difficult airway assessment. *J Clin Monit Comput* 2017; 31:513–30
- Ramsingh D, Frank E, Haughton R, Schilling J, Gimenez KM, Banh E, Rinehart J, Cannesson M: Auscultation versus point-of-care ultrasound to determine endotracheal versus bronchial intubation: A diagnostic accuracy study. *ANESTHESIOLOGY* 2016; 124:1012–20

22. Nicholls SE, Sweeney TW, Ferre RM, Strout TD: Bedside sonography by emergency physicians for the rapid identification of landmarks relevant to cricothyrotomy. *Am J Emerg Med* 2008; 26:852–6
23. Osman A, Sum KM: Role of upper airway ultrasound in airway management. *J Intensive Care* 2016; 4:52
24. Xirouchaki N, Magkanas E, Vaporidi K, Kondili E, Plataki M, Patrianakos A, Akoumianaki E, Georgopoulos D: Lung ultrasound in critically ill patients: Comparison with bedside chest radiography. *Intensive Care Med* 2011; 37:1488–93
25. Blaivas M, Lyon M, Duggal S: A prospective comparison of supine chest radiography and bedside ultrasound for the diagnosis of traumatic pneumothorax. *Acad Emerg Med* 2005; 12:844–9
26. Lichtenstein DA, Mezière GA: Relevance of lung ultrasound in the diagnosis of acute respiratory failure: The BLUE protocol. *Chest* 2008; 134:117–25
27. Siadecki SD, Frasure SE, Lewiss RE, Saul T: High body mass index is strongly correlated with decreased image quality in focused bedside echocardiography. *J Emerg Med* 2016; 50:295–301
28. Scalea TM, Rodriguez A, Chiu WC, Breneman FD, Fallon WF Jr, Kato K, McKenney MG, Nerlich ML, Ochsner MG, Yoshii H: Focused Assessment with Sonography for Trauma (FAST): Results from an international consensus conference. *J Trauma* 1999; 46:466–72
29. Haskins SC, Desai NA, Fields KG, Nejm JA, Cheng S, Coleman SH, Nawabi DH, Kelly BT: Diagnosis of intraabdominal fluid extravasation after hip arthroscopy with point-of-care ultrasonography can identify patients at an increased risk for postoperative pain. *Anesth Analg* 2017; 124:791–9
30. Perlas A, Van de Putte P, Van Houwe P, Chan VW: I-AIM framework for point-of-care gastric ultrasound. *Br J Anaesth* 2016; 116:7–11
31. Ostrom E, Joseph A: The use of musculoskeletal ultrasound for the diagnosis of groin and hip pain in athletes. *Curr Sports Med Rep* 2016; 15:86–90
32. American College of Emergency Physicians: Emergency ultrasound guidelines. *Ann Emerg Med* 2009; 53: 550–70
33. Subramaniam S, Bober J, Chao J, Zehtabchi S: Point-of-care ultrasound for diagnosis of abscess in skin and soft tissue infections. *Acad Emerg Med* 2016; 23:1298–306
34. Frankel HL, Kirkpatrick AW, Elbarbary M, Blaivas M, Desai H, Evans D, Summerfield DT, Slonim A, Breikreutz R, Price S, Marik PE, Talmor D, Levitov A: Guidelines for the appropriate use of bedside general and cardiac ultrasonography in the evaluation of critically ill patients—Part I: General ultrasonography. *Crit Care Med* 2015; 43:2479–502
35. Schmidt BE, Lam AM: “Wave” of the future in neuro-anesthesiology too! *Anesth Analg* 2017; 124:371
36. Nazerian P, Volpicelli G, Gigli C, Becattini C, Sferrazza Papa GF, Grifoni S, Vanni S; Ultrasound Wells Study Group: Diagnostic performance of Wells Score combined with point-of-care lung and venous ultrasound in suspected pulmonary embolism. *Acad Emerg Med* 2017; 24:270–80
37. Troianos CA, Hartman GS, Glas KE, Skubas NJ, Eberhardt RT, Walker JD, Reeves ST; Councils on Intraoperative Echocardiography and Vascular Ultrasound of the American Society of Echocardiography; Society of Cardiovascular Anesthesiologists: Special articles: Guidelines for performing ultrasound guided vascular cannulation: Recommendations of the American Society of Echocardiography and the Society of Cardiovascular Anesthesiologists. *Anesth Analg* 2012; 114:46–72
38. Practice guidelines for perioperative transesophageal echocardiography. An updated report by the American Society of Anesthesiologists and the Society of Cardiovascular Anesthesiologists Task Force on Transesophageal Echocardiography. *ANESTHESIOLOGY* 2010; 112:1084–96
39. Mayo PH, Beaulieu Y, Doelken P, Feller-Kopman D, Harrod C, Kaplan A, Oropello J, Vieillard-Baron A, Axler O, Lichtenstein D, Maury E, Slama M, Vignon P: American College of Chest Physicians/La Société de Réanimation de Langue Française statement on competence in critical care ultrasonography. *Chest* 2009; 135:1050–60
40. Pustavoitau A, Blaivas M, Brown SM, Gutierrez C, Kirkpatrick AW, Kohl BA, Oren-Grinberg A, Frankel HL: Recommendations for achieving and maintaining competence and credentialing in critical care ultrasound with focused cardiac ultrasound and advanced critical care echocardiography. Available at: <https://journals.lww.com/ccmjournal/Documents/Critical%20Care%20Ultrasound.pdf>. Accessed January 1, 2020.
41. Conlin F, Roy Connelly N, Raghunathan K, Friderici J, Schwabauer A: Focused transthoracic cardiac ultrasound: A survey of training practices. *J Cardiothorac Vasc Anesth* 2016; 30:102–6
42. American Medical Association Policy: Privileging for ultrasound imaging, H-230.960, 1999. Available at: <https://policysearch.ama-assn.org/policyfinder/detail/Ultrasound%20imaging?uri=%2FAMADoc%2FHOD.xml-0-1591.xml>. Accessed January 1, 2020.
43. Accreditation Council for Graduate Medical Education Program Requirements for Graduate Medical Education in Anesthesiology, effective July 1, 2019. Available at: [https://www.acgme.org/Portals/0/PFAssets/ProgramRequirements/040\\_Anesthesiology\\_2019\\_TCC.pdf?ver=2019-03-21-161242-837](https://www.acgme.org/Portals/0/PFAssets/ProgramRequirements/040_Anesthesiology_2019_TCC.pdf?ver=2019-03-21-161242-837). Accessed January 1, 2020.
44. Primary Certification in Anesthesiology. Available at: <http://www.theaba.org/PDFs/BASIC-Exam/Basic-and-Advanced-ContentOutline>. Accessed November 18, 2018.



45. Ramsingh D, Alexander B, Le K, Williams W, Canales C, Cannesson M: Comparison of the didactic lecture with the simulation/model approach for the teaching of a novel perioperative ultrasound curriculum to anesthesiology residents. *J Clin Anesth* 2014; 26:443–54
46. Blehar DJ, Barton B, Gaspari RJ: Learning curves in emergency ultrasound education. *Acad Emerg Med* 2015; 22:574–82
47. De Marchi L, Meineri M: POCUS in perioperative medicine: A North American perspective. *Crit Ultrasound J* 2017; 9:19
48. McCormick TJ, Miller EC, Chen R, Naik VN: Acquiring and maintaining point-of-care ultrasound (POCUS) competence for anesthesiologists. *Can J Anaesth* 2018; 65:427–36
49. Resnick J, Hoffenberg S, Tayal V, Dickman E: Ultrasound coding and reimbursement document 2009. Emergency Ultrasound Section, American College of Emergency Physicians. Available at: [http://emergencyultrasoundteaching.com/assets/2009\\_coding\\_update.pdf](http://emergencyultrasoundteaching.com/assets/2009_coding_update.pdf). Accessed January 1, 2020.
50. Thomas-Mohtat R, Sable C, Breslin K, Weinberg JG, Prasad A, Zinns L, Cohen JS: Interpretation errors in focused cardiac ultrasound by novice pediatric emergency medicine fellow sonologists. *Crit Ultrasound J* 2018; 10:33
51. Nelson TR, Fowlkes JB, Abramowicz JS, Church CC: Ultrasound biosafety considerations for the practicing sonographer and sonologist. *J Ultrasound Med* 2009; 28:139–50